



PRESENTING CLINICAL SIGNS

DATE History: Grade 2/6 murmur. Pre-anesthetic evaluation (dental).

ECHOCARDIOGRAPHIC FINDINGS

2D, M-mode, and Doppler study.

PERFORMED BY

Kim Liedberg

INTERPRETED BY

Keith Blass, DVM,
MS, DACVIM
(Cardiology)

Left atrial size is normal. The mitral valve appears normal, though trace mitral regurgitation is present. Left ventricular dimensions are normal. Left ventricular systolic function is normal. The aorta and aortic valve appear normal, though there is mildly increased flow velocity in the ascending aorta. Right atrial and right ventricular dimensions are normal. The tricuspid valve appears normal, though trace tricuspid regurgitation is present. The pulmonary artery and pulmonic valve are normal. No shunting lesions are visualized. No pericardial effusion or cardiac masses are seen.

PATIENT

Shadow Stark

LA - 40.0 mm
LVIDd - 41.3 mm
LVIDs - 27.6 mm
FS - 33%
RA - 25.8 mm
LVOT - 2.07 m/s
RVOT - 1.32 m/s

SPECIES

Canine

ASSESSMENT/RECOMMENDATIONS

Normal echocardiogram

BREED

Soft-Coated Wheaten
Terrier

This examination demonstrates no evidence of structural heart disease, as trace regurgitation of blood across Shadow's mitral and tricuspid valves can be considered normal physiology variants. Shadow's murmur appears to be due to the presence of mildly increased flow velocity in her aorta, which is a common reason for a functional/innocent murmur to develop in dogs.

Shadow's cardiovascular risk for general anesthesia is low based on this exam, and there are no contraindications to the use of any specific anesthetic agents.

SEX

FS

No therapy is recommended based on this exam.

A recheck echocardiogram is recommended if the characteristics of Shadow's murmur change, or if other new physical exam and/or clinical abnormalities suggestive of cardiac dysfunction develop.

AGE

4 y

WEIGHT

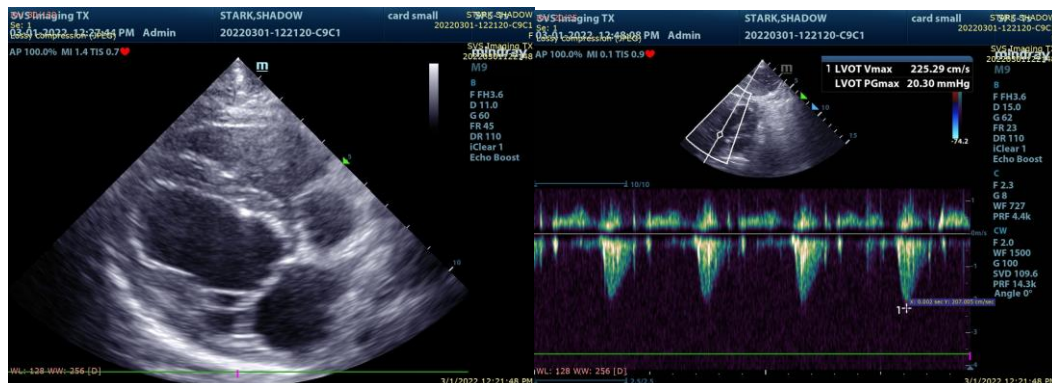
48.7 lb

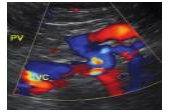
HOSPITAL NAME

SVS Imaging WI

REFERRING VET

Dr. Bittner





DATE

3/1/22

The information and recommendations provided are based on the images presented by the referring veterinarian. No evaluation can be communicated regarding pathology that was not visible in the image/video clips provided.

Thank you for this referral. If the clinical or image interpretation does not parallel your findings or if I can be of any further assistance please contact me.

PERFORMED BY

Kim Liedberg

Keith Blass, DVM, MS, DACVIM (Cardiology)
KeithBlass@gmail.com
631-804-5754

INTERPRETED BY

Keith Blass, DVM,
MS, DACVIM
(Cardiology)

PATIENT

Shadow Stark

SPECIES

Canine

BREED

Soft-Coated Wheaton
Terrier

SEX

FS

AGE

4 y

WEIGHT

48.7 lb

HOSPITAL NAME

SVS Imaging WI

REFERRING VET

Dr. Bittner